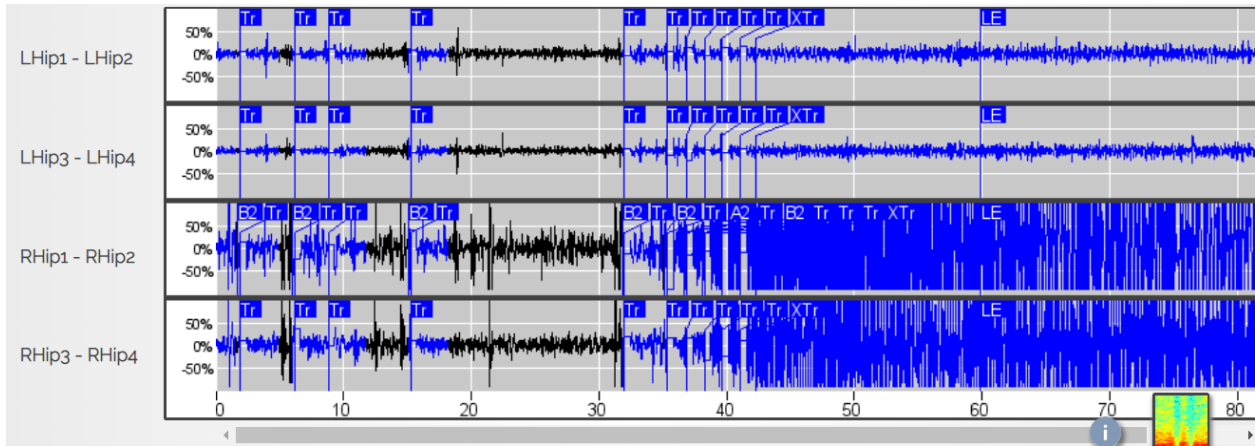


**Figure 1:** Example unilateral MTL onset which stays exclusively on the right MTL in patient 8



Example of a right MTL onset with seizure spread to the left MTL in patient 8

